

Motor nerve conduction of common Peroneal nerve in young adult.

Sunil Chouhan

Department of Physiology, Gandhi Medical College, Bhopal (M.P.), India

Abstract

The motor Nerve conduction studies was done in CPN (common peroneal nerve) in fifty healthy male and female subject, 16-20 year of age. The values were establish for comparisons and references. The Amplitude of motor and were divided into different components and computerized machine was used to analyze the DL, Amplitude and conduction velocities. The CPN Motor studies gave DL of 4.09 ms, Amplitude of 6.58 mv and CV of 52.31m/sec. For Proposing normative value, these measurement are an adequate way for Electrophysiological evaluation of the Motor CPN, which latter on can be used by the clinician while dealing with this nerve.

Keywords: Nerve conduction velocity (NCV),

Accepted June 02 2012

Introduction

For establishing normative data to provide additional reference value, this study was undertaken in Department of physiology, NSCB Medical college, Jabalpur. From this study reference value for motor and sensory conduction velocity of CPN has been obtained.

Usually, CPN which is a branch of sciatic nerve supply both anterior and peroneal compartment of the leg, begin at the apex of popliteal fossa and on reaching fibula neck, this CPN nerve curve round the neck deep to peroneus longus [1]. It divide into superficial and deep peroneal nerve distal to fibular neck [2].

CPN Neuropathy evaluation can be done by localizing the site and nature of lesion. The conduction velocity measurement of the concern nerve in healthy subject can be used as a diagnostic tool to differentiate it from abnormal [3,4]. In the region of head and neck of fibula, CPN can be damage either by compression or direct trauma (4). Some of the common cause of compression are wearing high heel boot/shoe, plaster casts, leg bras, Stocking or from sitting with the leg crossed for pronged period [3]. Also after surgery of total knee replacement [5] and arthroscopy of the knee [6,7], it is liable to get injured. Inversion injury of ankle is one of the less common cause of CP neuropathy [8,9]. In one study, even experience neurophysian /clinician fail to Diagnose CP neuropathy clinically before electrophysiological

evaluation was done [10]. The prognosis depend on severity of nerve damage which depend on conduction block which take lesser time as compared to axonal damage. The prognosis can be found out by NC Studies and normal reference value can be compared with abnormal values [3]. The aim is therefore to assess the different parameter which latter can be used to compare with pathological cases.

Material and Method

On the basis of past and present history, selection of subject was made and Median nerve NCV was done to avoid possible subclinical neuropathy.

Motor NCV

1. Active surface electrode – placed over the digito rum Brevis.(Fig-1)
2. Reference surface electrode – Placed over the base of little toe.(Fig-1)
3. Ground surface electrode – Placed over the dorsum aspect of foot. (Fig-1)

Fifty student of first MBBS underwent electromyography. The machine used was “computerized Neurocare 2000 machine, manufactured by Bio-tech india, Mumbai Before applying surface Electrodes. Before Applying surface electrode on the skin, the skin was cleaned with

spirit. The disposable electrode was placed as mention above. The stimulus was given to the Nerve at two point with the help of stimulator. First distally at the ankle which is 2 cm distal to the fibular neck later to the arterial tibial tendon. Secondly proximally in the lateral part of popliteal space. Using supramaximal stimulus, the recording of the nerve was made.

The distance between active electrode and stimulating point was measured which was latter used to calculate NCV of concern segment. Latency, Amplitude, CV parameter were studied and data were expressed as Mean and S.D. On the basis of data, Normal NCV of the above mention nerve was proposed.

Result / Observation

Fifty (50) 1st year MBBS students (Male =25;Female-25), aged between 16-20 year (Mean=19.16;S.D=0.73) were selected for Motor Nerve conduction studies of CPN. Mean, S.D, value along with other neurophysiological parameter studies shown in table-1. There was no significance difference between right and left side for Motor latency, Amplitude and NCV as per the paired “t” test. From above data, a reference value for CPN motor NCV, Amplitude and NCV were proposed, so that can be used by clinician while making diagnosis. The Motor NCV 52.30 m/sec(right leg) / 52.41 m/sec(left leg) were slightly higher to those of previous studies [14].

Table 1. Motor Nerve conduction studies - Common peroneal nerve.

Stimulation	Parameter	Latency (millisecond)		Amplitude (millivolt)		NCV (meter per second)	
		Right	Left	Right	Left	Right	Left
Ankle	Mean	4.09	4.09	6.58	6.41		
	SD (±)	0.72	0.67	2.42	1.86		
	Significance	P>0.05		P>0.05		P>0.05	
Head of Fibula	Mean	10.65	10.64	5.91	5.67	52.31	52.41
	SD (±)	0.81	0.86	2.26	2.24	7.68	8.07
	Significance	P>0.05		P>0.05		P>0.05	

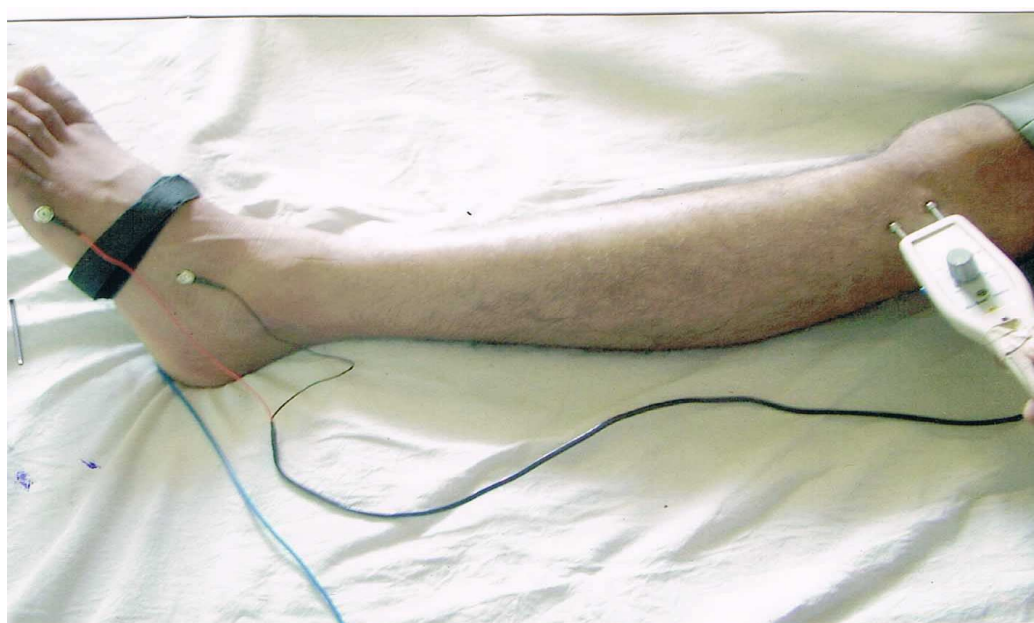

Figure 1. Electrode placements of motor CPN

Motor nerve conduction of common Peroneal nerve in young adult.

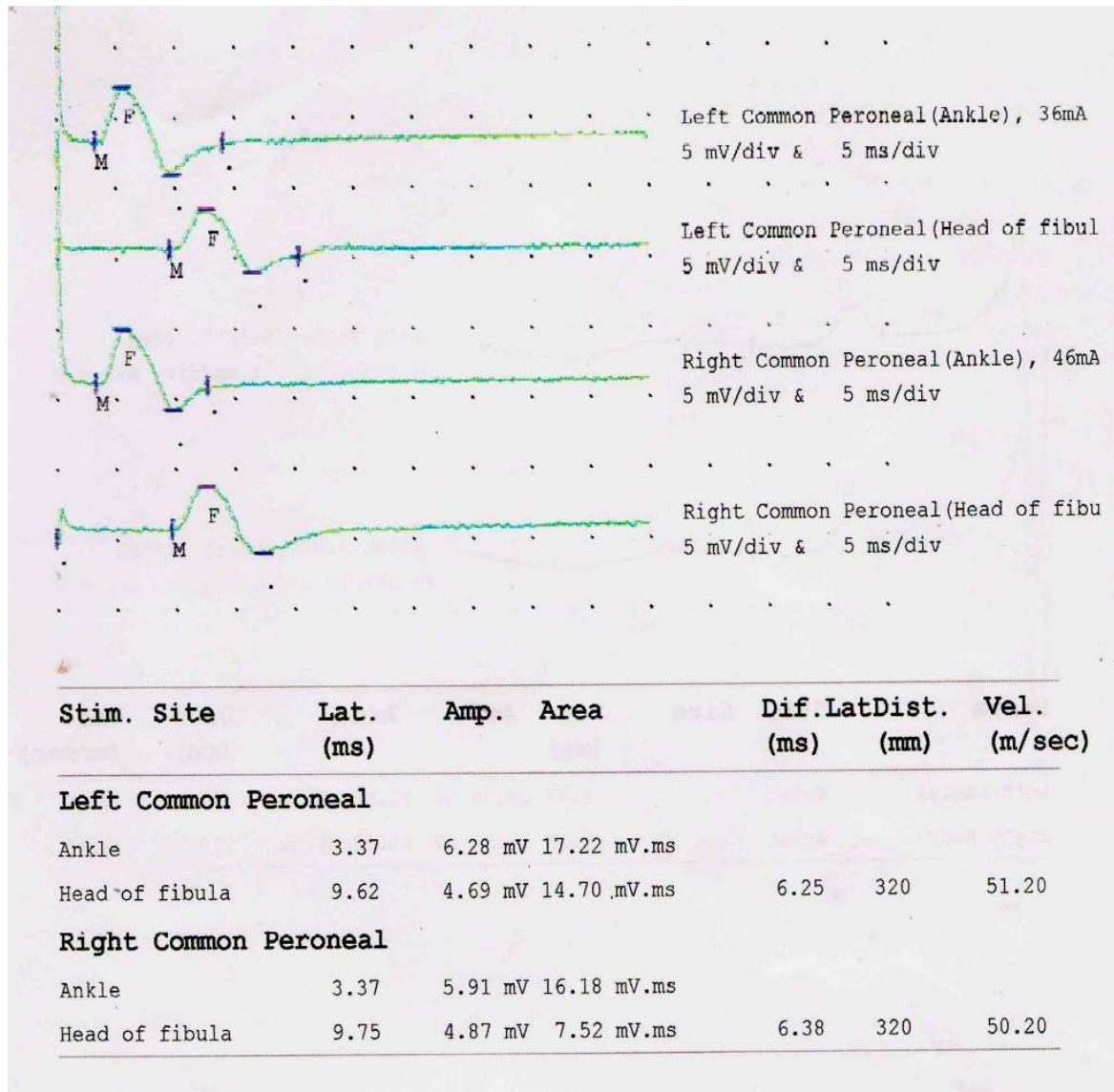


Figure 2. Computerized machine showing Motor NCV of Right and left CPN.

Discussion

Over the year EMG has been used as a simple non-invasive technique for diagnosis, monitoring and prognostic evaluation of nerve injury and neuropathy [11]. Many studies have come out with and without control parameter like temperature. In setup where facilities of control temperature is not established which affect NCV [12] this proposed study give normal reference value for electrophysiological evaluation of CPN. Even through Ultra-sound guided, block at the level of fibular head can be found out [13]. There is no significant difference between the right and left side of any of the variables taken into consideration in this study. Further for establishment of normative value further study are required keeping in view of the Indian rural hospital setup, where facilities for diagnosis of neuropathy is very

poor. Reference normative value can help a lot to the clinician while making a decision regarding diagnosis and progress of the nerve injury concern.

Acknowledgements

I'm obliged and thankful to Dr. Usha Chauhan, Retired Prof & Head, Department of Physiology NSCB Medical College, Jabalpur for her support and encouragement.

References

1. Malwatkar SG. Integrated text book of anatomy, Gross Anatomy, Embryology, Histology. Oxford university Press 1999.
2. Mishra UK. Clinical Neurophysiology. 2nd Ed B.I. Churchill livingstone.

3. Aminoff MJ-Electromyography in clinical practice.3rd Ed, Churchill living stone.
4. Thomas PK, Sears TA, Gilliat RW. The range of conduction velocity in normal motor nerve fibers to the small muscles of the hand and foot. *J Neurol Neurosurg Psychiatry*. 1959; 22: 175-181.
5. Kaushal SP, Galante JO, McKenna R, etc. Complication following total knee replacement. *Clin Orthop* 1976; 121: 181.
6. Jurist KA, Greene PW 3rd, Shirkhoda A. Peroneal nerve dysfunction as a complication of lateral meniscus repair: a case report and anatomic dissection. *Arthroscopy*. 1989; 5 (2): 141-147.
7. Esselman PC, Tom ski MA :Isolated deep peroneal nerve injury as a complication of arthroscopic surgery of the knee. *Muscle nerve* 1991; 14: 880.
8. Meals RA. Peroneal-nerve palsy complicating ankle sprain. Report of two cases and review of the literature. *J Bone Joint Surg Am*. 1977; 59 (7): 966-968.
9. Stoff MD, Greene AF. Common peroneal nerve palsy following inversion ankle injury: a report of two cases. *Phys Ther* 1982; 62 (10): 1463-1464.
10. Katirji MB, Wilbourn AJ. Common peroneal mononeuropathy: a clinical and electrophysiologic study of 116 lesions. *Neurology*. 1988; 38 (11): 1723-1728.
11. Silva PF, Lima MC, Figueiroa JN, Lins OG. *Arq Neuropsiquiatr*. Temporal branch of facial nerve: a normative study of nerve conduction 2010; 68 (4): 619-622.
12. Yuasa J, Kishi R, Harabuchi I, Eguchi T, Arata Y, Fujita S, Miyake H. Effects of age and skin temperature on peripheral nerve conduction velocity--a basic study for nerve conduction velocity measurement in worksite. *Sangyo Eiseigaku Zasshi*. 1996 Jul;38(4):158-64. Japanese.
13. Ting PH, Antonakakis JG, Scalzo DC. Ultrasound-guided common peroneal nerve block at the level of the fibular head. *J Clin Anesth*. 2012; 24 (2): 145-147.
14. Bayramoglu FG, Dalkilic N, Kiziltan E, Demirel I. Deep peroneal motor nerve conduction velocity distribution and correlation between nerve conduction groups and the number of innervated muscle fibers. *Int J Neurosci*. 2004; 114 (9): 1147-1159.

Correspondence to:

Sunil Chouhan
 F -5/33, Charimli
 Bhopal. 462016 (M.P.)
 India